



Kate Barker

Simon Rogers

Bisphosphonate-Associated Osteonecrosis of the Jaws: A Guide for the General Dental Practitioner

Abstract: Bisphosphonates are used most commonly in the management of metastatic malignant disorders to bone and for osteoporosis. The number of patients on treatment is increasing. Although there is clear evidence of medical efficacy, there are increasing numbers of reports concerning bisphosphonate-associated osteonecrosis of the jaws. This side-effect poses significant problems and is very difficult to treat.

The aim of this article is to outline the proposed pathogenesis, incidence, presenting signs and symptoms, and risk factors. Also, suggestions are made as to the most appropriate measures for prevention and management of bisphosphonate-associated jaw osteonecrosis.

Clinical Relevance: General dental practitioners have a key role to play in identifying patients at risk of developing bisphosphonate-associated osteonecrosis of the jaws, preventing occurrence of the condition and initiating early specialist referral.

Dent Update 2006; 33: 270-275

The general dental practitioner needs to be aware of the potential for bisphosphonate treatment to contribute to serious oral complications. Recently, a number of publications have implicated bisphosphonate therapy in the onset of 'osteonecrosis'.^{1,2,3} The problem is likely to become more common as the number of patients and duration of time on oral or intravenous bisphosphonate therapy increases.⁴

Definition

Bisphosphonate jaw necrosis is

defined as exposed, a vascular, non-healing bone in either the mandible or maxilla in association with current or previous intravenous or oral bisphosphonate therapy.² It may present spontaneously but it is usually precipitated by either an invasive dental procedure or trauma to the mucosa.

What are bisphosphonates?

Although the action of bisphosphonates has been appreciated for many years, it has only been in the last decade that they have become routinely used in the management of metastatic bone disease and osteoporosis.^{5,6} They are non-metabolized analogues of pyrophosphate. They exert their effect by binding to bone and osteoclasts, followed by internalization of the drug and irreversible inhibition of function.¹ The latest generation of bisphosphonate drugs commonly prescribed in the

United Kingdom includes alendronate (Fosamax, Merck), risedronate (Actonel, Aventis), pamidronate (Aredia, Novartis), and zoledronate (Zometa, Novartis) (Table 1). All four of these represent a third generation of bisphosphonates that contain a nitrogen group and have greater potency and better selectivity at lower concentrations than their first generation predecessors.⁷ Bisphosphonate medications may be prescribed for a range of conditions, including osteoporosis, Paget's disease, multiple myeloma, hypercalcaemia of malignancy, and bone metastases of malignancies such as breast and prostate cancer.

Oral bisphosphonate therapy forms part of the management of osteoporosis and is more common than intravenous bisphosphonate use for cancer.^{8,9,10} While all forms of bisphosphonates may potentially increase the risk of jaw osteonecrosis, the intravenous form is more potent than the

Kate Barker, BDS(Hons), Senior House Officer in Oral and Maxillofacial Surgery and **Simon Rogers**, FDS RCS, FRCS MD, Consultant and Honorary Reader, University Hospital Aintree, Longmoor Lane, Liverpool, UK.

Administration of Bisphosphonate	Examples of 3rd generation Bisphosphates	Dose frequently prescribed
Oral Bisphosphonates	1. Alendronate (Fosamax, Merck)	1. 70 mg per week
Treatment of Osteoporosis	2. Risedronate (Actonel, Aventis)	2. 35 mg per week
IV Bisphosphonates	1. Pamidronate (Aredia, Novartis)	1. 90 mg per month
Treatment of Cancer	2. Zoledronate (Zometa, Norvartis)	2. 4 mg per month

Table 1. Commonly prescribed bisphosphonates, their product name(s), use and dosage.

oral medications, and more frequently associated with complications.^{10,11} This is mainly explained by the poor enteral absorption of oral bisphosphonate, thus relatively reducing its bioavailability.⁷

Pathogenesis and associated causative factors

Although the exact mechanism underlying bisphosphonate-mediated osteonecrosis is unknown, there is evidence that bisphosphonates may inhibit the function of osteoclasts in several ways, including:

- Inhibiting osteoclast development from

precursor cells;

- Increasing osteoclast apoptosis;
- Stimulating osteoclast inhibitory factor;
- Reducing osteoclast activity; and
- The down-regulation of matrix metalloproteases.¹²

Bisphosphonates in the bloodstream bind avidly to the bone and, with slow bone turnover, it is thought that the half-life in bone of intravenous preparations may be as long as ten years.⁴ The predilection of bisphosphonate-associated osteonecrosis for the jaws has not been fully explained. One suggestion is that there may be an inability of hypodynamic and hypovascular bone to meet an increased demand for repair and remodelling owing to physiologic stress (mastication), iatrogenic trauma, eg tooth extraction, or tooth infection in an environment that is bacteria-laden.¹³ Co-existing risk factors that increase the risk of bisphosphonate-associated necrosis include:

- Therapy with corticosteroids;
- Chemotherapy;
- Medical co-morbidities such as diabetes mellitus; and
- The presence of dental disease.

However, cases have developed after long-term use of oral bisphosphonates for the treatment of osteoporosis with no other relevant medical history.^{11,14}

Incidence

The true incidence of bisphosphonate jaw osteonecrosis is unknown. In 2003, Marx first described a series of 36 cases of exposed necrotic bone detected in patients who were receiving intravenous pamidronate or zoledronate bisphosphonate therapy.² In a

2004 retrospective review of patients with refractory osteomyelitis and a history of chronic bisphosphonate therapy, Ruggiero *et al.* reported 63 cases of bisphosphonate-associated osteonecrosis over a 4-month period.¹ Since then, there have been over 200 reported cases of bisphosphonate-associated osteonecrosis of the jaw bones in the literature. While the majority of reported cases worldwide are associated with the intravenous bisphosphonates zoledronate and pamidronate, there are documented reports of osteonecrosis associated with the oral bisphosphonates, alendronate and risedronate.^{1,2,7,9}

More than 300 000 patients worldwide have received the injectable bisphosphonate zoledronate for hypercalcaemia of malignancy.¹⁰ In 2003, alendronate was listed as the nineteenth most commonly prescribed drug, with 17 million prescriptions worldwide.¹⁰ In South Australia in 2003, approximately 14 000 patients received prescriptions for the second and third generation bisphosphonates, only five cases of jaw necrosis were reported by maxillofacial surgeons/dentists/oncologists throughout the state.¹² Therefore, although still difficult to determine, the incidence of bisphosphonate-related osteonecrosis of the jaws appears to be relatively low.

Clinical features

Osteonecrosis of the jaw presents to dentists as an exposure of the mandible or the maxilla that can be either painful or asymptomatic. Although jaw necrosis can occur spontaneously without any recognized cause, most patients present with non-healing sockets following exodontia.¹⁴ Any insult which denudes

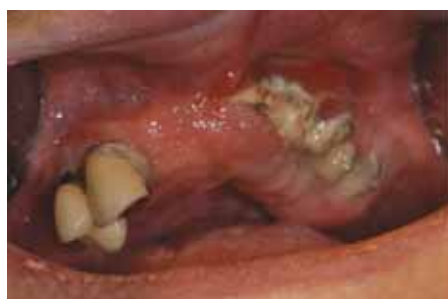

Figure 1. Exposed bone of the maxilla; osteonecrosis associated with bisphosphonate therapy.

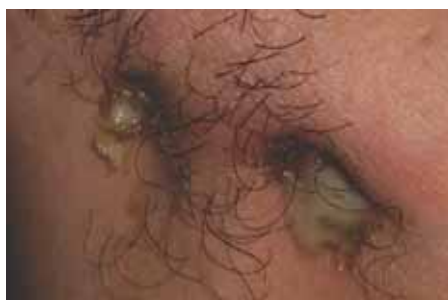

Figure 2. Discharging cutaneous sinuses.

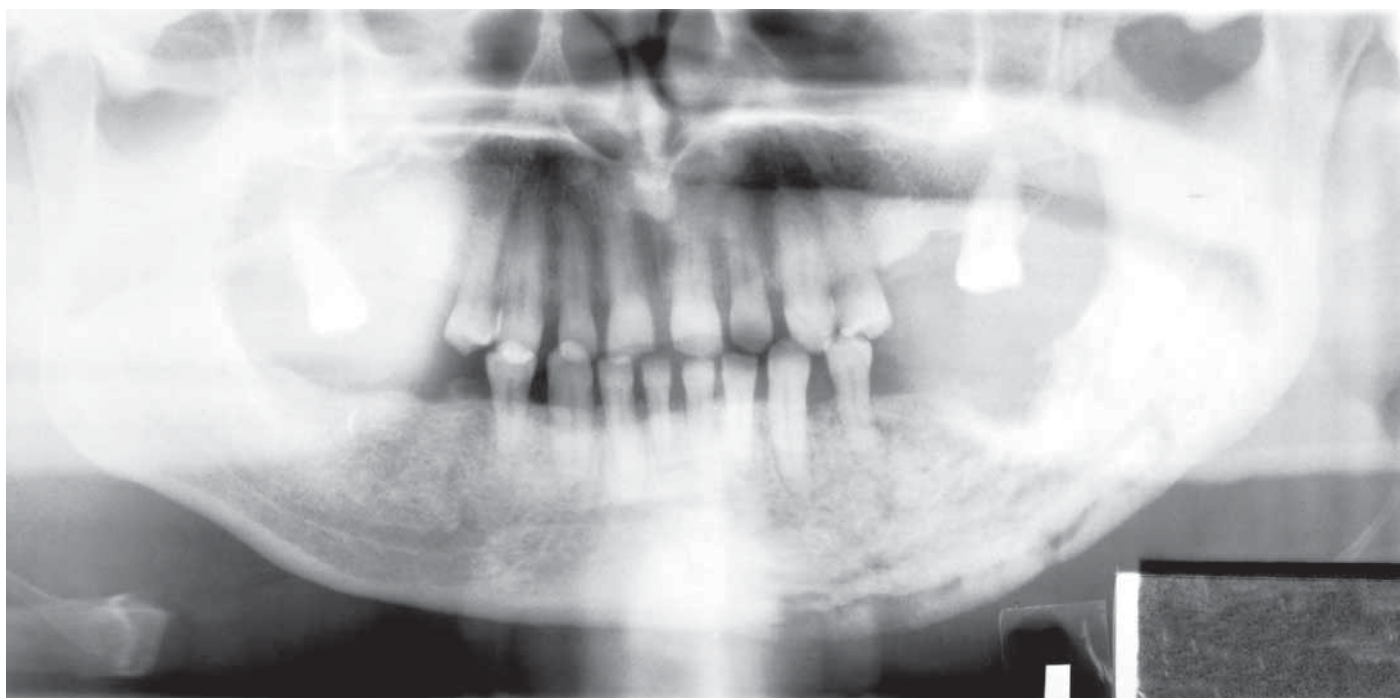


Figure 3. OPG showing evidence of mottled bone in the region of a non-healing extraction site.

bone may potentially lead to osteonecrosis in this patient group, such as implants, minor oral surgery, or ill-fitting dentures.^{2,3} The clinical presentation may also include localized pain, numbness and altered sensation, loosening of teeth, soft tissue infection and swelling.^{2,7,15} Such features can occur prior to the development of clinical osteonecrosis. Established osteonecrosis (Figure 1) is often painful and may be progressive, leading to large areas of sequestration and bone loss. Occasionally, extra-oral sinuses (Figure 2) or pathological fracture can occur. Radiographically, there is often evidence of mottled bone consistent with osteolysis (Figure 3).

Prevention and treatment of patients receiving bisphosphonate therapy

Recently, a panel of experts in the USA from the specialties of oral and maxillofacial surgery, oral medicine, endocrinology, and medical oncology developed recommendations to reduce the incidence of osteonecrosis of the jaws.¹¹ For patients receiving intravenous bisphosphonate therapy, the following was

suggested prior to the commencement of the drug:

- A thorough dental examination and necessary tooth extractions with time for healing is recommended;
- Rehabilitation of the dentition, including endodontic therapy;
- Dental prophylaxis, caries control;
- Ensuring proper fit of dentures;
- Oral hygiene education, including use of chlorhexidine mouthwash.

For patients already receiving bisphosphonates, it was suggested that:

- Prophylactic antibiotic therapy is not required before routine dentistry unless otherwise indicated.
- Close collaboration between the dentist and surgical/medical oncologist is essential.

It would seem prudent to take measures to prevent osteonecrosis in those potentially at risk. This includes appropriate preventive dentistry with caries control, avoiding invasive periodontal procedures or dental implant placement and using soft liners on dentures.^{7,11} Preventive use of chlorhexidine mouthwash is recommended. Dental infections should be managed non-surgically with root canal therapy and minimal surgical intervention because it

appears that extractions precipitate the majority of cases of osteonecrosis. If a tooth is unrestorable, root canal treatment with coronal amputation should be considered. Care should be taken in the placement of rubber dam clamps to avoid mucosal injury that may precipitate inflammation and soft tissue loss. Patients requiring extractions should probably best be referred. Should chronic bone exposure occur, referral to an appropriate specialist is essential.

For those patients receiving oral bisphosphonate therapy, the risk of osteonecrosis appears to be very low.^{1,13} It is still vital to practise preventive dental measures and manage dental infections non-surgically where possible. Extractions are not contra-indicated in this group of patients. However, the authors would suggest that the following points seem appropriate:

- Use of chlorhexidine mouthwash before and after extractions;
- Careful follow-up until healing of the socket has completed;
- Atraumatic extractions where possible with the avoidance of raising mucoperiosteal flaps;
- Although there is no consensus on the

use of antibiotics, consideration should be given to oral prophylaxis of a broad spectrum antibiotic one hour prior to the extraction.¹⁵ It would seem worthwhile to consider extending the course for a week or so until there is clear evidence of bone healing.

Among patients receiving oral bisphosphonates in whom osteonecrosis develops, withdrawal of the drug until the condition is controlled may be warranted.

Management of established jaw necrosis

In general, established osteonecrosis is resistant to treatment, and surgical attempts to resolve the problem often lead to a worsening of the situation.^{2,3,11} The mainstay of conservative treatment is pain control and the management of infection. Combination analgesia might be necessary (eg paracetamol and codeine phosphate) and, on occasion, opioid analgesics are required. Also, symptomatic relief can be achieved by the use of mouthrinses and antibiotic therapy in the presence of infection.^{11,16} The goal of antibiotic therapy is to control osteomyelitis as well as soft tissue infection. In some patients, intermittent use of antibiotics is not effective in symptom control, and long-term therapy, such as the use of tetracyclines, has to be considered. Advice from the local oral microbiologist is valuable. Although bacteria culture and sensitivity is appropriate, there is uncertainty as to which antibiotics are most appropriate and this is reflected in the various antibiotic regimens that have been suggested in the literature:¹³

- Long-term use of penicillin + 0.12% chlorhexidine;
- For more refractory cases, metronidazole can be added to the regime;
- For those patients with a penicillin allergy, a combination of ciprofloxacin/clindamycin + metronidazole is recommended.

Local debridement of necrotic bone (sequestrectomy), even in the presence of 'healthy' oral mucosa, may help in the control of symptoms, but seems relatively ineffective in achieving healing. Often a persistent area of exposed jaw remains. Radical resection appears to be of limited value and is reserved for extreme cases. Hyperbaric oxygen therapy seems

ineffective.^{17,18} It is unclear if stopping bisphosphonate therapy will help in bone healing because the half-life is so long and patients often need to remain on intravenous treatment for the control of metastatic cancer.

Conclusion

There is an urgent need to raise awareness about the potential jaw-related problems associated with bisphosphonate therapy. There is particular concern regarding the dental care of patients who are about to commence, or have been on, intravenous bisphosphonates. Broad guidelines for the management of these patients have been presented in this article. At the moment, there are uncertainties about the significance of oral bisphosphonates but, as they are commonly used as part of the management of osteoporosis, it is important to document them in patients' medical history and to be aware of any potential problems that might arise.

References

1. Ruggiero SL, Mehrotra B, Rosenberg TJ, Engroff SL. Osteonecrosis of the jaws associated with the use of Bisphosphonates: a review of 63 cases. *J Oral Maxillofac Surg* 2004; **62**: 527–534.
2. Marx RE. Letters to the editor. Pamidronate (Aredia) and zoledronate (Zometa) induced vascular necrosis of the jaws: a growing epidemic. *J Oral Maxillofac Surg* 2003; **61**: 1115–1117.
3. Bagan JV, Murillo J, Jimenez J *et al*. Avascular jaw osteonecrosis in association with cancer chemotherapy: series of 10 cases. *J Oral Pathol Med* 2005; **34**: 120–123.
4. Chabner BA. Late toxicities of drugs: Bisphosphonates. *Oncologist* 2005; **10**: 310–313.
5. Food and Drug Administration Centre for Drug Evaluation and Research. *Oncologic Drugs Advisory Committee Meeting: Aredia/Zometa*. Rockville, MD: US Food and Drug Administration; March 4, 2005.
6. Wood J, Bonjean K, Ruetz S *et al*. Novel antiangiogenic effects of the bisphosphonate compound zoledronic acid. *J Pharmacol Exp Ther* 2002; **302**: 1055–1061.

7. Sarathy A, Bourgeois S, Goodell G. Bisphosphonate associated osteonecrosis of the jaws and endodontic treatments. *J Endod* 2005; **10**: 759–763.
8. *Technology Appraisal Guidance 87*. London: National Institute for Health and Clinical Excellence; Jan 2005.
9. Lipton A, Coleman RE, Diel IJ, Mundy G. Update on the role of bisphosphonates in metastatic breast cancer. *Semin Oncol* 2001; **28**: 2–91.
10. Hellstein J, Marek C. Bisphosphonate osteochemonecrosis (Bis-Phossy Jaw): is this Phossy Jaw of the 21st Century? *J Oral Maxillofac Surg* 2005; **63**: 682–689.
11. Novartis Pharmaceuticals Corporation. *Important drug precaution for dental health professionals with patients being treated for cancer* (letter to dentists). Rockville, MD: US Food and Drug Administration; May 5, 2005.
12. Carter G, Goss A, Doeke C. Bisphosphonates and avascular necrosis of the jaw: a possible association. *Med J Aust* 2005; **182**: 413–415.
13. Kantas AN, Rogers SN, Martin MV. A practical guide for patients undergoing exodontia following radiotherapy to the oral cavity. *Dent Update* 2002; **29**: 498–503.
14. Bagan JV. Letter to the Editor. Jaw osteonecrosis associated with bisphosphonates: multiple exposed areas and its relationship to teeth extractions. Study of 20 cases. *Oral Oncol* 2006; **42**: 327–329.
15. Marx RE, Sawatari Y, Fortin M, Broumand V. Bisphosphonate-induced exposed bone (osteonecrosis/osteopetrosis) of the jaws: risk factors, recognition, prevention, and treatment. *J Oral Maxillofac Surg* 2005; **63**: 1567–1575.
16. Durie BGM, Katz M, Crowley J. Letter to the Editor. Osteonecrosis of the jaw and bisphosphonates. *N Engl J Med* 2005; **353**: 99–100.
17. Woo SB, Handle K, Richardson PG. Letter to the Editor. Osteonecrosis of the jaw and bisphosphonates. *N Engl J Med* 2005; **353**: 100.
18. Maerevoet M, Martin C, Duck L. Letter to the Editor. Osteonecrosis of the jaw and bisphosphonates. *N Engl J Med* 2005; **353**: 100–101.