

Orofacial Disease: Update for the Dental Clinical Team: 7. Complaints Affecting Particularly the Palate or Gingivae

CRISPIAN SCULLY AND STEPHEN PORTER

Abstract: Certain lesions are exclusively or typically found in specific sites. This article discusses in detail conditions that occur mostly on the palate or gingivae.

Dent Update 1999; 26: 308 – 313

Clinical Relevance: A variety of disorders can affect the palate or gingivae. The majority of these are benign and/or congenital, however some arise secondary to systemic disorder or therapy and/or may be the consequence of local or distant malignancy

Surprisingly few conditions are found in the palate, although torus palatinus is a common developmental abnormality and erythematous candidosis may affect the palate.

Acquired palatal swellings are often dental abscesses but neoplasms, particularly salivary, Kaposi's sarcoma and lymphomas must be excluded.

Denture-induced stomatitis is a common complaint in the palate; it is usually asymptomatic but there may be an associated angular stomatitis.

White lesions may be seen, especially in smoker's keratosis and candidosis. Ulceration of the palate is uncommon except in pemphigus and lupus erythematosus.

Most generalized gingival swellings are due to hyperplasia related to plaque and are occasionally secondary to hormonal changes (puberty, pregnancy) or drugs, although gingival

swelling is sometimes congenital. Discrete gingival lumps (epulides) may be fibrous, pyogenic granulomas, giant cell lesions or neoplasms.

Desquamative gingivitis is not a disease entity but a clinical term for persistently sore, glazed and red or ulcerated gingivae. It is fairly common, arises almost exclusively in middle-aged or elderly women and is usually a manifestation of atrophic lichen planus or mucous membrane pemphigoid. Gingival ulcers are typical of necrotizing gingivitis and herpetic stomatitis, but may occur rarely in other infections, especially in deep fungal infections, in dermatological disorders and with neoplasms.

The first article in this series presented several general observations on diagnosis and treatment which should be borne in mind in relation to this article.

LESIONS OF THE PALATE

Erythematous Candidosis

This was discussed in Article 5 of this series (White lesions: *Dent Update*

1999; 26: 123 – 129); an example is illustrated in Figure 1.

Denture-induced Stomatitis

Also known as denture sore mouth or chronic atrophic candidosis, this is diffuse erythema limited to the denture-bearing area.

Aetiology

Denture-induced stomatitis is found only in people who wear appliances (usually dentures or orthodontic plates) and almost exclusively under an upper

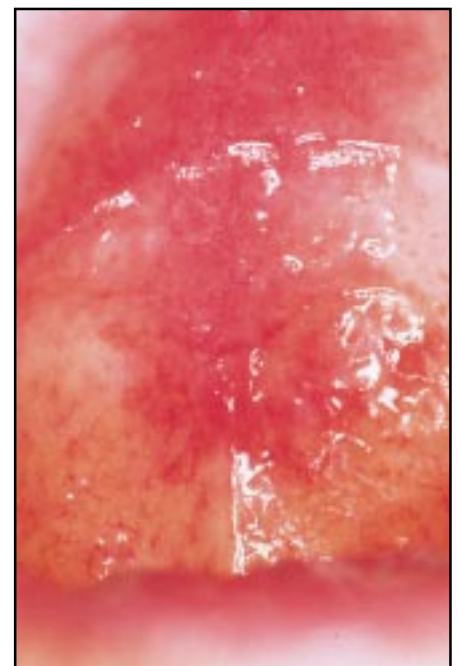

Figure 1. Candidosis: erythematous palatal lesion.

Crispian Scully, PhD, MD, MDS, FDS RCPS, FFD RCSI, FDS RCS, FDS RCSE, FRCPath, FMedSci, Professor, and **Stephen Porter**, PhD, MD, FDS RCSE, FDS RCS, Professor, Eastman Dental Institute for Oral Health Care Sciences, University of London.

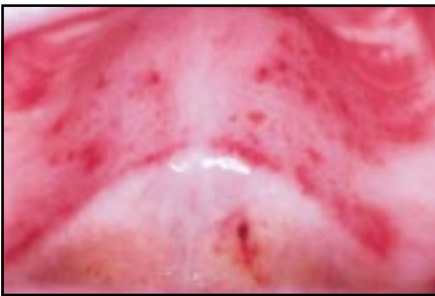


Figure 2. Candidosis: early lesions in denture-induced stomatitis.

appliance. The condition appears to be related to the proliferation of microorganisms beneath and within the appliance fitting surface. *Candida albicans* seems to be the main causal agent. It is unclear exactly what predisposes those affected to the candidosis but as they are not predisposed to candidosis elsewhere, local rather than systemic factors are likely to be crucial.

Denture-induced stomatitis affects only the fitting surface—making it quite clear that the condition is not caused by an allergic reaction, which would affect any mucosa in contact with the appliance. Trauma is also an unlikely cause, because there is less trauma beneath an upper appliance than a lower one. Other likely causative factors may include poor denture hygiene, xerostomia and, rarely, HIV infection.

Clinical Features

Denture-induced stomatitis presents with erythema limited to the denture-bearing area, typically beneath a complete upper denture. Early lesions may be punctate (Figure 2) but later may become diffuse (Figure 3). After many years papillary hyperplasia may

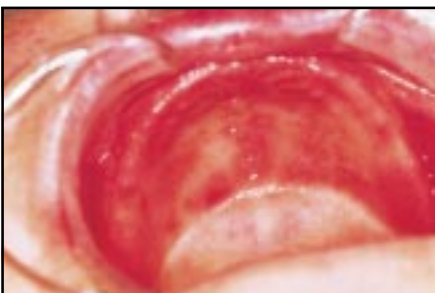

Figure 3. Candidosis: later lesions in denture-induced stomatitis.

appear, typically in the palatal vault (Figure 4). Denture-induced stomatitis is usually asymptomatic but there may be an associated angular stomatitis.

Management

- Improve denture hygiene.
- Keep dentures out of the mouth at night.
- Clean and store dentures in 1% hypochlorite or 0.2% aqueous chlorhexidine.
- Use antifungals—usually miconazole (mainly required where there is also angular stomatitis).
- Attention to dentures (see Table 1).

Smoker's Palate

This is also known as smoker's keratosis, nicotinic stomatitis or stomatitis palatini. It is an uncommon diffuse white lesion in the palate of (usually) pipe smokers.

- This is a common condition
- It appears mainly in persons wearing dentures throughout the night
- It is often caused by overgrowth of yeasts under, and in the surface of, dentures
- It does not appear to be transmissible
- The main consequence can be soreness at the angles of the mouth
- It is best treated by leaving the denture out of the mouth at night
- A plastic denture should be stored and cleaned in an antifungal such as hypochlorite
- The dentist may advise you to use an antifungal medication

Table 1. Patient information: denture-induced stomatitis

Aetiology

Smoker's keratosis is seen among heavy, long-term pipe smokers and some cigar smokers. By contrast, there

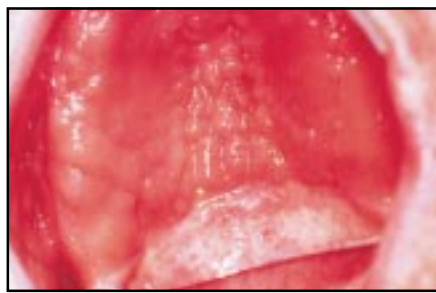


Figure 4. Candidosis: papillary hyperplasia in denture-induced stomatitis.

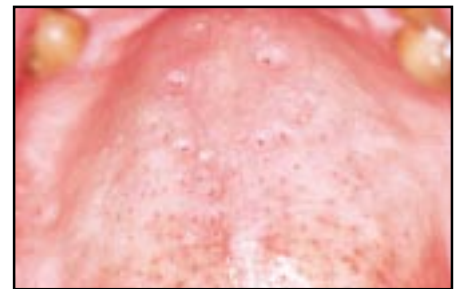

Figure 5. Smoker's keratosis.

is no characteristic type of hyperkeratotic lesion associated with the far more common habit of cigarette smoking.

Clinical Features

Smoker's keratosis is distinctive in that:

- there is white thickening of the palatal mucosa associated with small umbilicated swellings with red centres (Figure 5);
- the palate only is affected;
- any part of the palate protected by a denture is spared (Figure 6).

There are two components to smoker's keratosis: hyperkeratosis and inflammatory swelling of minor mucous glands. Either may predominate.

Pipe smoking raises the risk of cancer but this typically appears not in the palate but low down in the mouth, often in the lingual retromolar region, possibly as a result of carcinogens pooling in drainage areas of the mouth.

Diagnosis and Management

The clinical appearance and history are so distinctive that biopsy is not normally necessary. The patient should be encouraged to stop the causative habit.

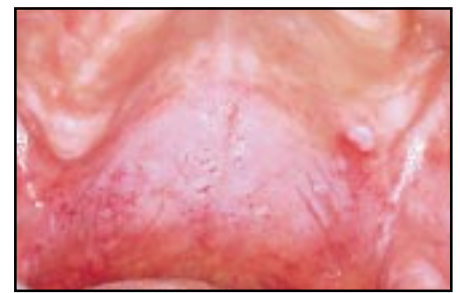

Figure 6. Smoker's keratosis.

SWELLINGS OF THE PALATE

Lumps of the hard palate may develop from structures within the palate (intrinsic) or beyond it (extrinsic).

Swellings include congenital conditions such as unerupted teeth, especially permanent canines or second premolars, and torus palatinus. Acquired conditions causing swellings include:

- dental abscess pointing on the palate (usually from the palatal roots of the first and second maxillary molars or from maxillary lateral incisors);
- fibrous lumps;
- papillomas;
- carcinomas;
- Kaposi's sarcoma;
- pleomorphic adenomas and other salivary neoplasms;
- invasive carcinoma from the maxillary sinus;
- fibrous dysplasia;
- Paget's disease.

Torus Palatinus

This is a common painless exostosis with a bony, hard, smooth or nodular surface. It is developmental in origin and benign in nature. Torus palatinus occurs in the centre of the hard palate. The overlying mucosa is normal. Tori are common conditions, usually of no consequence, apart from occasionally interfering with denture construction.

Kaposi's Sarcoma

This rare sarcoma has a bluish appearance and is seen almost

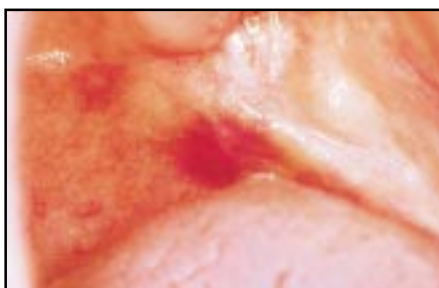

Figure 7. Kaposi's sarcoma.

exclusively in immunocompromised persons, mainly adult men.

Aetiology

Kaposi's sarcoma is a malignant endothelial tumour induced by a recently described virus—human herpesvirus 8. Kaposi's sarcoma of the mouth is almost exclusively seen in sexually transmitted AIDS, especially in male homosexuals or bisexuals, or other immunocompromised patients.

Clinical Features

Kaposi's sarcoma occurs primarily in the skin and mucosa in the head and neck. It typically commences as a red, bluish or purple (sometimes brown) macule which then enlarges to a nodule and may ulcerate. The lesions are frequently seen in the palate, over the greater palatine vessels (Figure 7), but may be seen elsewhere. Usually the oral lesions are part of much more widespread disease.

Diagnosis and Management

The diagnosis of Kaposi's sarcoma is often fairly obvious but specialist referral is usually indicated. It may be necessary to differentiate from other pigmented lesions, especially haemangiomas, purpura and epithelioid angiomatosis. The last is a bacterial infection (*Bartonella (Rochalimaea) henselae*) and responds to antibiotic treatment.

Biopsy is confirmatory. The underlying predisposing condition should be identified if possible. An HIV test may be indicated after appropriate counselling. Oral lesions respond transiently to radiotherapy, to vinca alkaloids systemically or intralesionally, or to intralesional sclerosing agents or interferon.

LOCALIZED GINGIVAL LUMPS AND SWELLINGS

Rapidly developing localized lumps, usually associated with discomfort, are most likely to be abscesses. Other localized swellings are usually inflammatory or neoplastic, and include:

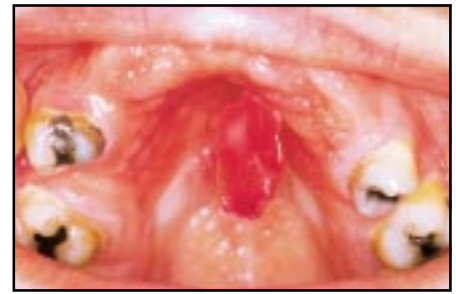

Figure 8. Fibrous lump.

- pregnancy epulis;
- fibroepithelial epulis;
- giant cell epulis;
- Crohn's disease and orofacial granulomatosis;
- sarcoidosis;
- papillomas;
- carcinomas;
- Kaposi's sarcoma;
- lymphoma;
- Wegener's granulomatosis.

Fibrous Epulis

The term 'epulis' is applied to any lump arising from gingiva. The fibrous epulis resembles a fibroepithelial polyp, but also usually has an inflammatory component.

Aetiology

Probably chronic irritation.

Clinical Features

The variable inflammatory changes account for the different clinical presentations—from red, shiny and soft lumps to those which are pale, stippled and firm. Commonly, lesions are round, painless, pedunculated swellings arising from the marginal or papillary gingiva, sometimes adjacent to sites of irritation (e.g. a carious cavity); they rarely involve the attached gingiva, and rarely exceed 2 cm in diameter (Figure 8).

Diagnosis and Management

The diagnosis is clinical but most lesions need to be removed and examined histologically. Fibrous epulides should be removed down to the periosteum, which should be curetted thoroughly.

Giant Cell Epulis

Aetiology

The resorption of deciduous teeth and remodelling of the alveolus at the mixed dentition stage indicate the osteoclastic potential of the area from which giant-cell epulides originate. The lesion probably arises because chronic irritation triggers a reactionary hyperplasia of mucoperiosteum and excessive production of granulation tissue. Giant-cell granulomas are also a feature of hyperparathyroidism.

Clinical Features

The giant cell epulis characteristically arises interdental, adjacent to permanent teeth which have had deciduous predecessors. Classically, the most notable feature is the deep red colour, although older lesions tend to be paler.

Diagnosis and Management

Biopsy is usually required to establish the diagnosis. In order to exclude hyperparathyroidism, levels of plasma calcium, phosphate and alkaline phosphatase should be assayed and the area examined radiographically: specialist referral is thus indicated.

Treatment depends on the cause. Any hyperparathyroidism must be medically treated. Treatment otherwise is surgical.

Wegener's Granulomatosis (Disseminated Malignant Granuloma)

This is a rare, potentially lethal, disseminating granulomatous condition

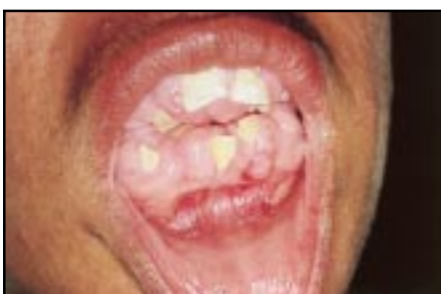

Figure 9. Hereditary gingival fibromatosis.

and is seen mainly in adults.

Aetiology

Unknown, possibly *Staphylococcus aureus*. There is necrotizing granulomatosis.

Clinical Features

This typically initially affects the respiratory tract. It is followed by widespread arteritis of small vessels, and renal damage. It may produce painless, progressive gingival enlargement that may have a fairly characteristic 'strawberry-like' appearance.

Swelling of the gingiva in a previously healthy mouth, particularly if associated with swollen, inflamed papillae, should arouse suspicion of this condition.

Diagnosis and Management

The diagnosis requires biopsy and pulmonary and renal investigations. Specialist care is needed. Cytotoxic therapy is usually needed, though there are reports of beneficial responses to antibiotics.

GENERALIZED GINGIVAL SWELLING

Sometimes swelling is congenital but most generalized gingival swellings are due to hyperplasia with oedema related to plaque deposits, occasionally exacerbated by hormonal changes (puberty, pregnancy) or drugs.

There are very few serious causes of generalized enlargements of the gingiva appearing spontaneously or rapidly but leukaemia is a prime suspect.

Causes of generalized enlargement include:

- gingival fibromatosis;
- leukaemia;
- gingival hyperplasia due to mouth breathing, pregnancy or drugs such as phenytoin, cyclosporin or calcium-channel blockers;
- vitamin C deficiency;
- sarcoidosis;
- Crohn's disease;

- orofacial granulomatosis;
- plasma cell gingivostomatitis.

Hereditary Gingival Fibromatosis

Aetiology

Hereditary gingival fibromatosis is an uncommon condition often transmitted by an autosomal dominant gene.

Clinical Features

The condition presents as generalized gingival enlargement, especially obvious during the transition from deciduous to permanent dentition. The changes involve the papillae and later the attached gingiva (Figure 9). If the enlargement is gross, it may move or cover the teeth and bulge out of the mouth. The affected gingiva is usually of normal colour but firm in consistency, and the surface, although initially smooth, becomes coarsely stippled. The family history is typically positive, and patients may also complain of hypertrichosis (excess hair). Rare patients have systemic syndromes of which this is one part.

Diagnosis and Management

Diagnosis is clinical. Surgery (scalpel, laser, or electro-) is often indicated.

Drug-induced Hyperplasia

Drug-induced hyperplasia is usually aggravated by poor oral hygiene. Papillae are firm and pale and enlarge to form false vertical clefts (Figure 10). Hypertrichosis (excess hair) may be associated with drug-induced gingival hyperplasia, as in congenital hyperplasia.

The anticonvulsant phenytoin often produces a variable amount of gingival enlargement, which characteristically affects the interdental papillae first but may later involve the marginal and even attached gingiva. The buccal and labial gingivae are mainly involved. The enlargement rarely affects

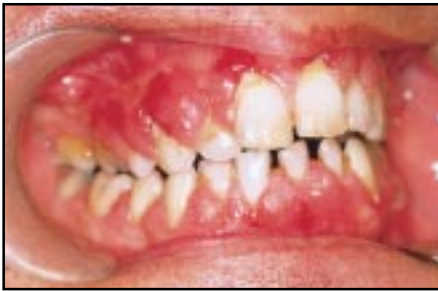

Figure 10. Drug-induced gingival hyperplasia.

edentulous sites. It is characteristically firm, pale and tough, with coarse stippling.

The immunosuppressive cyclosporin may produce gingival hyperplasia, initially of the papillae.

Nifedipine (an antihypertensive agent) and other calcium-channel blockers may cause gingival hyperplasia typically affecting the papillae, which become red and puffy and tend to bleed.

Enlargements related to use of oral contraceptives may rarely arise.

Diagnosis and Management

Such changes often develop slowly—over weeks rather than days—and are usually painless. It may be possible to change or reduce the dose of the causative drug in consultation with the patient's physician. Otherwise, improvements to the oral hygiene and gingival surgery are the mainstays of therapy.

Pregnancy Gingivitis and Pregnancy Epulis

Aetiology

Exacerbation of chronic gingivitis by pregnancy. Poor oral hygiene

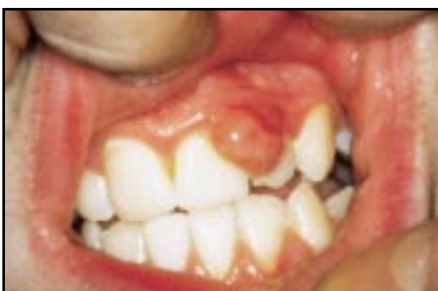

Figure 11. Pregnancy epulis.

predisposes to changes which are a result of increased progestogen levels.

Clinical Features

Pregnancy gingivitis is characterized by:

- soft, reddish enlargements, usually of the gingival papillae;
- mainly labial location of swelling;
- gingival bleeding, particularly on eating or toothbrushing.

Sometimes there is a localized gingival lump—a pregnancy epulis (Figure 11).

Changes appear first about the second month of pregnancy, and reach a peak at the eighth month.

Changes may revert soon after parturition to the previous level of gingival health.

Diagnosis and Management

Histologically, a pregnancy epulis is a pyogenic granuloma. Conservative treatment is indicated unless an epulis interferes with occlusion or is extremely unsightly—when it may be excised. In any event, oral hygiene should be meticulous.

Scurvy

Deficiency of vitamin C (ascorbic acid) results when no fresh fruit or vegetables are eaten for a long period. This is rare in developed countries.

Clinical Features

Lesions include:

- diffusely swollen, boggy and purplish gingivae with purpura and haemorrhage; and
- perifollicular haemorrhages of the skin.

Diagnosis and Management

The diagnosis will be clear from the dietary history and clinical features. The classic investigation is assay of white cell ascorbic acid; however, this is rarely required. Vitamin C supplements should be given and the diet reformed.

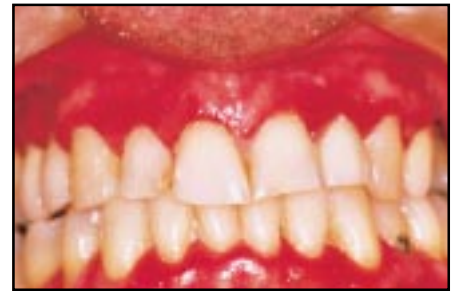

Figure 12. Desquamative gingivitis.

Desquamative Gingivitis

Desquamative gingivitis is not a disease entity but a clinical term for persistently sore, glazed and red or ulcerated gingivae. It is fairly common, seen almost exclusively in middle-aged or elderly women.

Aetiology

Desquamative gingivitis is usually a manifestation of atrophic lichen planus or mucous membrane pemphigoid, and occasionally seen in pemphigus or other dermatoses.

Clinical Features

The main features include:

- persistent gingival soreness, which worsens on eating;
- red and glazed (patchily or uniformly) gingivae, especially labially (Figure 12);
- loss of the distinct junction between attached gingivae and vestibular mucosae.

The gingival margins and edentulous ridges tend to be spared. The erythema is exaggerated where oral hygiene is poor.

Other oral or cutaneous lesions of dermatoses may be associated.

Diagnosis and Management

The diagnosis is usually obvious from the history, with clinical findings, but other causes of red gingival lesions should be excluded (Table 2). Biopsy and immunostaining may be required to establish the precise cause, and thus specialist referral may be indicated.

Treatment should be of the underlying condition; if there are extra-oral lesions systemic therapy, usually with

- Gingivitis:**
- Inflammatory
 - Desquamative
 - Trauma
 - Drugs
- Infections such as primary herpetic stomatitis
 - Crohn's disease
 - Orofacial granulomatosis
 - Sarcoidosis
 - Erythroplasia
 - Plasma cell gingivostomatitis
 - Kaposi's sarcoma

Table 2. Gingival red lesions.

corticosteroids, may be required. The desquamative gingivitis can be improved if oral hygiene is increased and topical corticosteroids given as appropriate (Table 3). Corticosteroid creams used overnight in a polythene splint may help. Other available therapies include cyclosporin, dapsone and tetracyclines.

GINGIVAL BLEEDING

Most gingival bleeding is due to inflammatory periodontal disease, sometimes exaggerated by hormonal changes such as occur during pregnancy, but haemorrhagic disease (including leukaemia) and drugs are occasionally responsible.

FURTHER READING

Burton J, Scully C. The lips. In: Champion RH, Burton J, Burns DA, Breathnach SM, eds.

Textbook of Dermatology, 6th ed. Oxford: Blackwell, 1998; pp.3125-3148.

Eversole LR. Immunopathology of oral mucosal ulcerative, desquamative and bullous diseases. Selective review of the literature. *Oral Surg Oral Med Oral Pathol* 1994; **77**: 555-571.

Eveson JW, Scully C. *Colour Atlas of Oral Pathology*. London: Mosby-Wolfe, 1995.

Jones JH, Mason DK. *Oral Manifestations of Systemic Disease*, 2nd ed. London: Baillière-Tindall, 1980.

Millard HD, Mason DK, eds. *Perspectives on 1993 World Workshop on Oral Medicine*. Chicago: University of Michigan.

Porter SR, Scully C. Periodontal aspects of systemic disease. A system of classification. In: Lang N, ed. *European Workshop of Periodontology*. Chicago: Quintessence, 1994; pp.374-419.

Porter SR, Scully C. Periodontal aspects of systemic disease. Some therapeutic concepts. In: Lang N, ed. *European Workshop of Periodontology*. Chicago: Quintessence, 1994; pp.415-438.

Scully C, *Handbook of Oral Diseases*. London: Martin Dunitz, 1999.

Scully C, Cawson RA. *Medical Problems in Dentistry*, 4th ed. Oxford: Butterworth-Heinemann, 1998.

Scully C, Flint S, Porter S. *Oral Diseases*. London: Martin Dunitz, 1996.

Scully C, Welbury R. *Colour Atlas of Oral Disease in Children and Adolescents*. London: Mosby-Wolfe, 1994.

Scully C, Porter SR, Mutlu S. Markers of disease susceptibility and activity for periodontal diseases: changing subject-based risk factors. In: Johnson NW, ed. *Risk Markers for Oral Disease: 3. Periodontal Diseases*. Cambridge: Cambridge University Press, 1991; pp.139-178.

Scully C, Porter SR. Oral mucosal disease: a decade of new entities, aetiologies and associations. *Int Dent J* 1994; **44**: 33-43.

Scully C. Diagnosis and diagnostic procedures: general and soft tissue diagnosis. In: *Pathways in Practice*. Faculty of General Dental Practice,

Royal College of Surgeons of England, 1993; pp.25-33.

Scully C. Prevention of oral mucosal disease. In: Murray JJ, ed. *Prevention of Oral and Dental Disease*, 3rd ed. Oxford: Oxford University Press, 1995; pp.160-172.

Scully C. The oral cavity. In: Champion RH, Burton J, Burns DA, Breathnach SM, eds. *Textbook of Dermatology*, 6th ed. Oxford: Blackwell, 1998; pp.3047-3124.

Scully C. The pathology of orofacial disease. In: Barnes IE, Walls AWG, eds. *Gerodontology*. Oxford: Wright, 1994; pp.29-41.

Wray D, Lowe G, Bagg J, Felix D, Scully C. *Textbook of General and Oral Medicine*. Edinburgh: Livingstone, 1999.

ABSTRACTS

HOW BRIGHT IS YOUR LIGHT?

A Survey of Output Intensity and Potential for Depth of Cure among Light-curing Units in Clinical Use. R Pilo, D Oelgiesser and H Cardash. *Journal of Dentistry* 1999; **27**: 235-241.

The depth of cure of VLC composites is dependant on both the properties of the material, and the intensity and duration of exposure to the visible light source. The presence of poorly polymerized composite beneath a restoration is of considerable concern. Not only are the mechanical properties and long-term retention compromised, but there are also residual monomers which may lead to staining, secondary caries, pulpal irritation and even systemic effects. A decrease of only 10% in light intensity may have a significant effect on polymerization only 2 mm beneath the surface of the restoration.

One hundred and thirty curing lights in general dental practices were assessed using curing and heat radiometers. The light intensity should be greater than 300 mW cm⁻². The results revealed a range of 25 (yes 25) – 825 mW cm⁻². Almost half of the lights tested required repair or replacement, and almost a third were deemed unusable according to their manufacturer's instructions. Other workers in this field report similar results.

When did you last check the output of the curing lights in your practice?

Peter Carrotte, Glasgow Dental School

Dental surgeon	Ancillary, Hygienist, Nurse
Understand disease and management in order to extend education of, and reassure, patient	Understand disease and management in order to extend education of, and reassure, patient
Establish a diagnosis; biopsy if necessary. Refer to specialist if extra-oral lesions or pemphigus suspected	Oral health education of patient
Initiate therapy, usually with topical corticosteroids and chlorhexidine	Help patient maintain good oral hygiene
Be alert to any possible adverse effects of treatment, such as candidosis	Alert Dental Surgeon to any changes, or possible adverse effects of treatment
Oral health care; in particular to avoid infection	
Oral health education of patient	

Table 3. Roles of the dental clinical team in the management of a patient with desquamative gingivitis.