

Maxillary odontogenic keratocyst

A common and serious clinical misdiagnosis

MOHAMMAD ALI, D.D.S.; RONALD A. BAUGHMAN, D.D.S., M.S.D.

Jaw cysts are very common due to the presence of odontogenic epithelium remnants.¹ Cysts constitute about 17 percent of the tissue specimens submitted to oral pathology biopsy services.² The periapical cyst is the most common odontogenic cyst (52.3-70.7 percent of all odontogenic cysts) followed by the dentigerous cyst (16.6-21.3 percent of all odontogenic cysts) and odontogenic keratocyst, or OKC (5.4-

The canine region is the most common location for the odontogenic keratocyst in the maxilla.

17.4 percent of all odontogenic cysts).²⁻⁵ OKC was categorized by the latest World Health Organization classification as a developmental, noninflammatory odontogenic cyst⁶ that arises from cell rests of dental lamina.⁷

OKCs have distinctive histologic feature that can distinguish them from other cysts. It is characterized by a uniform epithelial layer that lacks rete ridges. In addition, it has a corrugated parakeratinized luminal layer and a prominent basal cell layer. OKCs have a high recurrence rate and develop more aggressively than any other jaw cysts.^{4,8-10} Patients in their second and third decades of life are affected most commonly.¹¹⁻¹³

OKCs appear as well-defined radiolucencies, which can be either unilocular or multilocular.¹⁴ Unilocular OKCs can be located periapically, simulating periapical cysts^{11,15,16}; surrounding the crown of unerupted teeth, simulating dentigerous cysts^{11,17}; between the roots of teeth, simulating lateral periodontal cysts or lateral radicular cysts¹⁸; or in the maxillary midline, simulating nasopalatine duct cysts.⁹ Large unilocular OKCs can be indistinguishable from cystic ameloblastomas.^{20,21} Conventional radiographic imaging, such as panoramic

Background. The authors conducted this study to determine the most common location of odontogenic keratocysts, or OKCs, in the maxilla and the implication of this for dental practice.

Methods. The authors reviewed all cases diagnosed as an OKC by the Oral and Maxillofacial Pathology Diagnostic Laboratory at University of Florida College of Dentistry from July 1, 1993, to June 30, 2001. They determined the location for each cyst and recorded relevant clinical information such as age and sex. In addition, the authors noted the practitioners' clinical diagnoses for the cases in the most common location in the maxilla and compared them with the final diagnosis.

Results. A total of 398 OKCs occurred in 393 patients. Of the 398 cysts, 266 (66.8 percent) were in the mandible, and 132 (33.2 percent) were in the maxilla. The most common location for OKCs was the third molar and ramus area of the mandible, with 137 cysts. The canine region of the maxilla, with 54 cysts, was the second most common location. Submitting clinicians mentioned OKC as a diagnostic possibility in only 31.5 percent of the maxillary canine region cases.

Conclusion. The most common maxillary location for OKCs is the canine region where they commonly are mistaken for an apical inflammatory lesion or lateral periodontal cyst. Accurate diagnosis is essential for proper patient therapy and follow-up.

Clinical Implication. A diagnosis based solely on clinical information can be problematic. In many cases, histologic examination of surgically removed tissue is necessary to establish a definitive diagnosis. That is particularly true for cases that do not resolve when treated by conservative endodontic therapy.

views and intraoral periapical films, in most cases are adequate to determine the location and estimate the size of an OKC. Advanced imaging techniques like computerized tomography and magnetic resonance imaging can be useful in large cases involving the maxillary

sinus and the rare cases that extend to the skull base.²²⁻²⁴

Several studies of the clinical presentation of OKCs have been conducted. Most have shown that the mandible is involved more often than the maxilla.^{4,8,11,13,25-31} In addition, the posterior part of the mandible is the most common location for OKCs.^{8,11,12,25-31} There are inconsistencies regarding the predominant location of OKCs in the maxilla. One study shows that OKCs are divided equally between the anterior and the posterior maxilla,⁸ some show that there are more anterior lesions than posterior lesions,²⁵⁻²⁸ and others conclude that the posterior region is the predominant site.^{11-13,29,32}

We used a retrospective analysis to establish the most common location of OKCs in the maxilla and compared our findings with previous reports of maxillary OKCs.

METHODS

We reviewed all cysts diagnosed as OKCs by the Oral and Maxillofacial Pathology Diagnostic Laboratory at the University of Florida College of Dentistry from July 1, 1993, to June 30, 2001. We obtained information regarding each case from a microscopic analysis of hematoxylin-eosin-stained sections and from biopsy forms submitted by clinicians. We included in the study only cases that satisfied the following clinical and histopathologic criteria:

- adequate description of the anatomical location on the case history form;
- adherence to histologic features described by Pindborg and Hansen²⁶ for OKC;
- no recurrent lesions.

After selecting cases, we used the following criteria to define the locations of the lesions in each jaw:

- anterior—midline to distal surface of the lateral incisor;
- canine—distal surface of lateral incisor to mesial surface of the first premolar;
- premolar—mesial surface of the first premolar to the distal surface of the second premolar;
- first and second molar—distal surface of the second premolar to the distal surface of the second molar;
- third molar and ramus—distal surface of the second molar to the distal surface of the third

molar, including the ramus;

- third molar and tuberosity—distal surface of the second molar to the distal surface of the third molar, including the tuberosity.

In addition, we categorized the cysts as:

- periapical/radicular lesions—lesions appearing radiographically consistent with a periapical/radicular cyst;
- pericoronal lesions—lesions appearing radiographically consistent with a dentigerous cyst;
- lateral root lesions—lesions appearing consistent with a lateral periodontal cyst or lateral radicular cyst;
- lesions not associated with a tooth.

We recorded other clinical information such as age and sex for each case. We obtained information regarding the practitioner's clinical diagnoses from the biopsy forms for the cases in the most common maxillary location.

RESULTS

Location. Of the 513 cases we reviewed, 120 did not meet various criteria, and we excluded them. In 62 cases, the history was incomplete; in 16 cases, the lesion was too large; 36 cases were recurrent; and in six cases, classic histologic features of OKC described by Pindborg and Hansen²⁶ could not be identified with certainty due to the degenerative changes of the cystic epithelium secondary to intense inflammation in the wall. The pathologist (R.A.B.) initially diagnosed these six cases as "inflamed odontogenic cyst, suggestive of inflamed OKC." A total of 398 OKCs from 393 patients satisfied the criteria for this study. There were 266 (66.8 percent) OKCs in the mandible and 132 (33.2 percent) in the maxilla, a ratio of 2:1.

In the mandible, 137 (34.4 percent) cysts occurred in the third molar and ramus area, 41 (10.3 percent) in the premolar area, 41 (10.3 percent) in the canine area, 33 (8.3 percent) in the first and second molar area and 14 (3.5 percent) in the anterior area (Figure 1).

In the maxilla, 54 (13.6 percent) cysts occurred in the canine area, 30 (7.5 percent) in the third molar and tuberosity region, 28 (7.0 percent) in the anterior area, 13 (3.3 percent) in the first and second molar area and seven (1.8 percent) in the premolar area (Figure 2). We also recorded the position of the OKCs in relation to the teeth and

**The data demonstrate
 that in the
 maxillary canine
 region odontogenic
 keratocysts may
 mimic other lesions.**

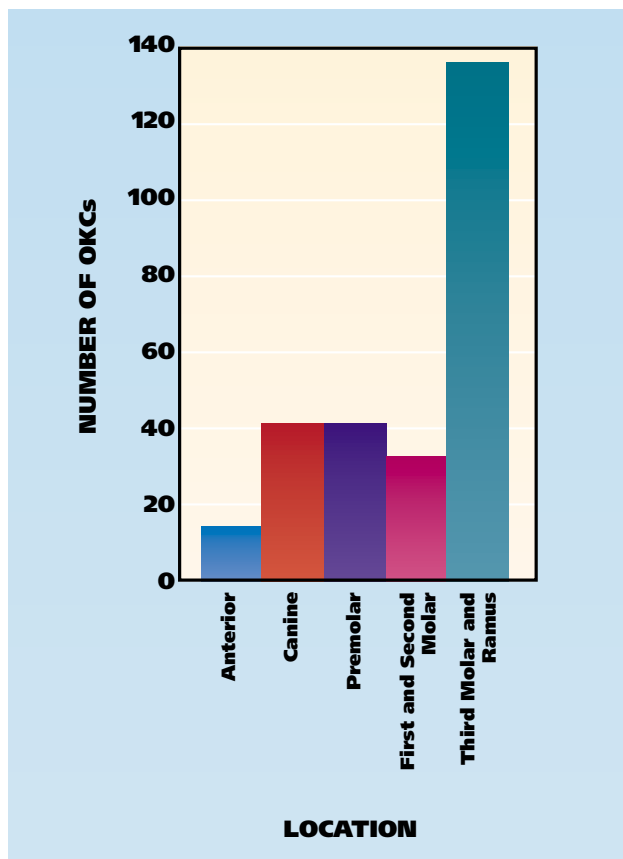


Figure 1. Location of 266 odontogenic keratocysts, or OKCs, in the mandible.

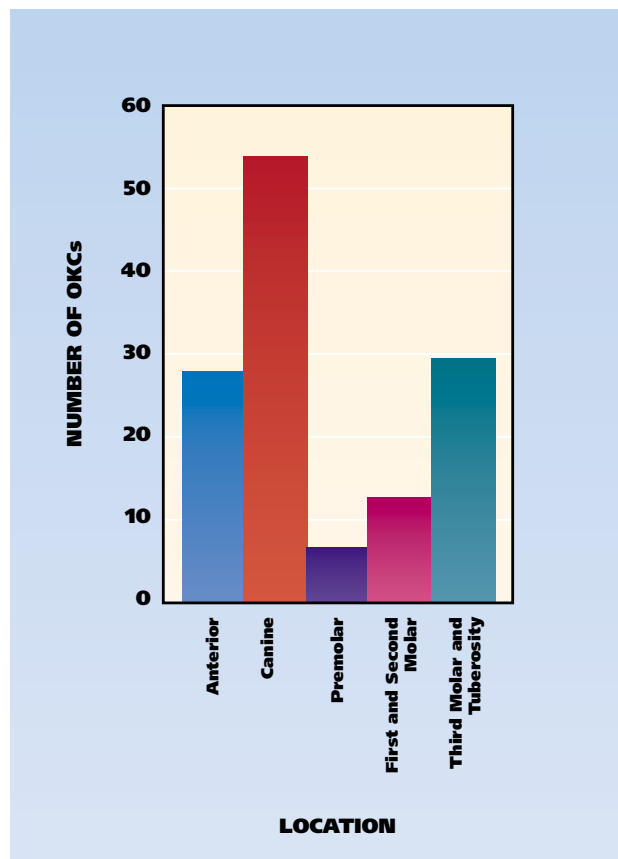


Figure 2. Location of 132 odontogenic keratocysts, or OKCs, in the maxilla.

show the relationships in Table 1.

The most common site of involvement was the mandibular third molar and ramus region with 137 (34.4 percent) OKCs. The next most common site was the canine region of the maxilla with 54 (13.6 percent).

Age. OKCs occurred in patients aged 10 to 94 years—a wide range of years. We show the age distribution in Figure 3. The peak incidence was 21.6 percent in the 70 to 79 years age group.

Sex. Of the 393 patients, 221 were male (56.2 percent), and 172 (43.8 percent) were female. In one case, the sex of the patient was unspecified. The male-to-female ratio was 1.3:1, constituting a slight male predisposition.

Maxillary canine region findings. Of the 132 maxillary cases, 54 (40.9 percent) occurred in the canine region. Of canine region OKCs, 27 were in the periapical/radicular position, and 25 were in the interproximal position. One cyst was

in the coronal position, and one cyst was not associated with a tooth or previous extraction site (Table 1).

The frequency of the clinical diagnoses submitted for the 54 cases in the maxillary canine region showed that OKC was mentioned as a diagnosis or one of the differential diagnoses in 17 (31.5 percent) cases, periapical cyst or granuloma in 14 (25.9 percent) cases, lateral periodontal cyst in 15 (27.8 percent) cases, globulomaxillary cyst in six (11.1 percent) cases, odontogenic tumor (adenomatoid odontogenic tumors, ameloblastoma and central giant cell granuloma) in five (9.3 percent) cases and dentigerous cyst in three (5.6 percent) cases (Table 2, page 881).

DISCUSSION

In our study, the age range was wide, from 10 to 94 years, with a peak incidence in the 70 to 79 years age group. Other studies reported a peak incidence in the second and third decades of life.¹¹⁻¹³

**Odontogenic
keratocysts occurred
in patients aged 10
to 94 years.**

TABLE 1

| POSITION OF ODONTOGENIC KERATOCYSTS IN RELATION TO TEETH. | | | | | |
|---|-------------------------------|----------------------|-----------------------|----------------------|-------------|
| ODONTOGENIC KERATOCYSTS | CATEGORY (NO.) | | | | CASES (NO.) |
| | Periapical/Radicular Position | Pericoronal Position | Lateral Root Position | Unassociated Lesions | |
| Mandibular | | | | | |
| Anterior | 12 | 0 | 2 | 0 | 14 |
| Canine | 10 | 4 | 27 | 0 | 41 |
| Premolar | 30 | 0 | 10 | 1 | 41 |
| First and second molar | 19 | 1 | 13 | 0 | 33 |
| Third molar and ramus | 15 | 52 | 0 | 70 | 137 |
| TOTAL | 86 | 57 | 52 | 71 | 266 |
| Maxillary | | | | | |
| Anterior | 19 | 0 | 9 | 0 | 28 |
| Canine | 27 | 1 | 25 | 1 | 54 |
| Premolar | 3 | 0 | 3 | 1 | 7 |
| First and second molar | 11 | 0 | 2 | 0 | 13 |
| Third molar and tuberosity | 10 | 12 | 0 | 8 | 30 |
| TOTAL | 70 | 13 | 39 | 10 | 132 |

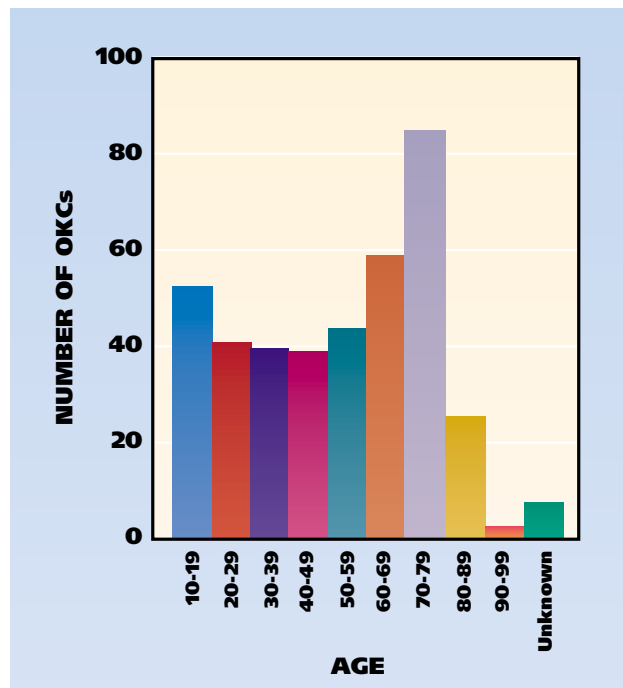


Figure 3. Age (years) distribution. OKCs: Odontogenic keratocysts.

Some investigators have reported a bimodal age distribution with an additional peak in the fifth¹⁰ and sixth²⁹ decades. The higher peak in our study may be due to the fact that it was conducted in Florida, which has a large retirement population. We found a male predominance by a ratio of 1.3:1, which is similar to previous reports.^{11-13,29} The mandible was found to be the most common location for the OKCs, with 266 (66.8 percent) of 398 cysts. The remaining 132 (33.2 percent) OKCs were located in the maxilla. The mandible-to-maxillary ratio was 2:1, which concurs with previous studies.^{8,11,26,31} The reported percentages of OKCs occurring in the mandible ranged from 65 percent to 83 percent in other studies.^{8,11-13,25,27-31} The most common mandibular site was the third-molar region with 34.4 percent of OKCs located there. Our findings are in close agreement with other studies.^{8,11,13,25-31,33}

In our study, the most common site for maxillary OKCs was in the canine region (54 cases, 13.6 percent). The maxillary canine region also was the second most common location overall. In the litera-

ture, there is disagreement about the most common location for maxillary OKCs. Payne⁸ reported that maxillary OKCs were divided equally between the anterior maxilla and the third molar tuberosity area. Panders and Hadders,²⁵ Pindborg and Hansen,²⁶ Hodgkinson and colleagues²⁷ and Chow²⁸ found that there were more anterior OKCs than posterior maxillary lesions. Brannon,¹¹ Browne,¹² Myoung and colleagues,¹³ Kakarantza-Angelopoulou and Nicolatou²⁹ and Haring and Van Dis³² reported that the posterior region of the maxilla is the predomi-

TABLE 2

| FREQUENCY OF CLINICAL DIAGNOSES IN THE MAXILLARY CANINE REGION.* | | |
|--|-----------|------------|
| CLINICAL DIAGNOSIS | FREQUENCY | PERCENTAGE |
| Odontogenic keratocyst | 17 | 31.5 |
| Lateral periodontal cyst | 15 | 27.8 |
| Periapical cyst/granuloma | 14 | 25.9 |
| Odontogenic cyst | 7 | 13.0 |
| Globulomaxillary cyst | 6 | 11.1 |
| Dentigerous cyst | 3 | 5.6 |
| Adenomatoid odontogenic tumor | 3 | 5.6 |
| Ameloblastoma | 1 | 1.9 |
| Central giant cell granuloma | 1 | 1.9 |
| Calcifying odontogenic cyst | 1 | 1.9 |

* N = 54 cases.

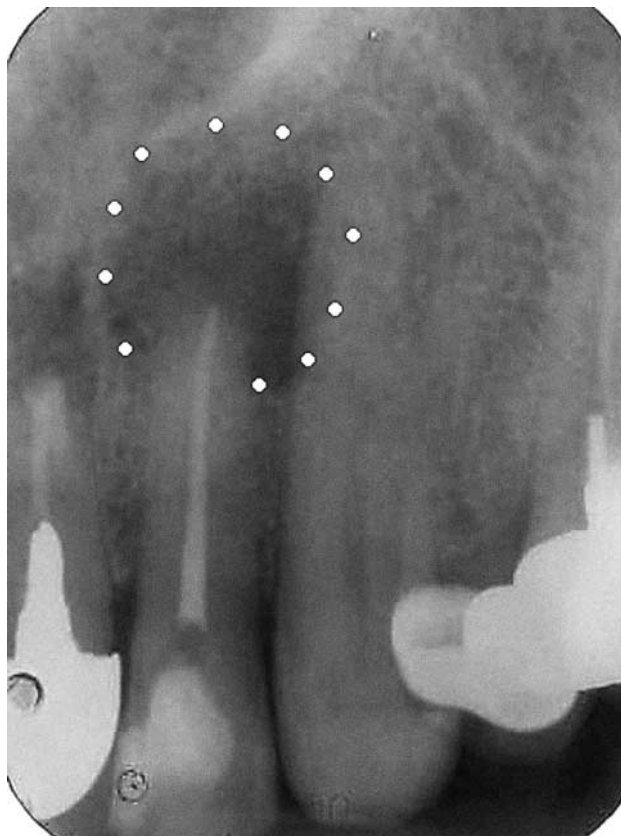

Figure 4. Unilocular odontogenic keratocyst in a peri-radicular area (circled by white dots) of a maxillary lateral incisor.

nant site. The number of reported cases in these studies ranged from 28 to 312.

In our study, further analysis of the maxillary canine region cases showed that OKC was mentioned as a diagnostic possibility by only 31.5 percent of the clinicians. The most popular clinical diagnoses were periapical cyst/granuloma and lateral periodontal cysts (Table 2).

These data demonstrate that in the maxillary canine region OKCs may mimic other lesions, especially inflammatory ones, making it difficult to determine the correct diagnosis based on clinical information alone. The difficulty in diagnosing OKCs based on radiographs alone has been recognized in other studies and was confirmed in our study.^{11,13-16,18,34,35} OKCs can be mistaken easily for inflammatory lesions because patients with this type of cyst usually have inflammatory symptoms such as pain, swelling and drainage.^{7,23,36} OKCs may appear as small unilocular radiolucencies³² and may occur adjacent to a nonvital or endodontically treated tooth¹⁶ (Figure 4 and Figure 5).

The main difference between OKCs and other jaw cysts are their potentially aggressive behavior. OKCs recur more often than any other type of jaw cyst.^{4,8,10} The recurrence rate is almost comparable to that of the ameloblastoma.^{4,33} The average recurrence rate is 30 percent,^{4,12,15,26-29,37-39} and a recurrence rate as high as 62 percent has been reported.²⁶ One of the suspected contributing factors for the high recurrence rate is the pres-

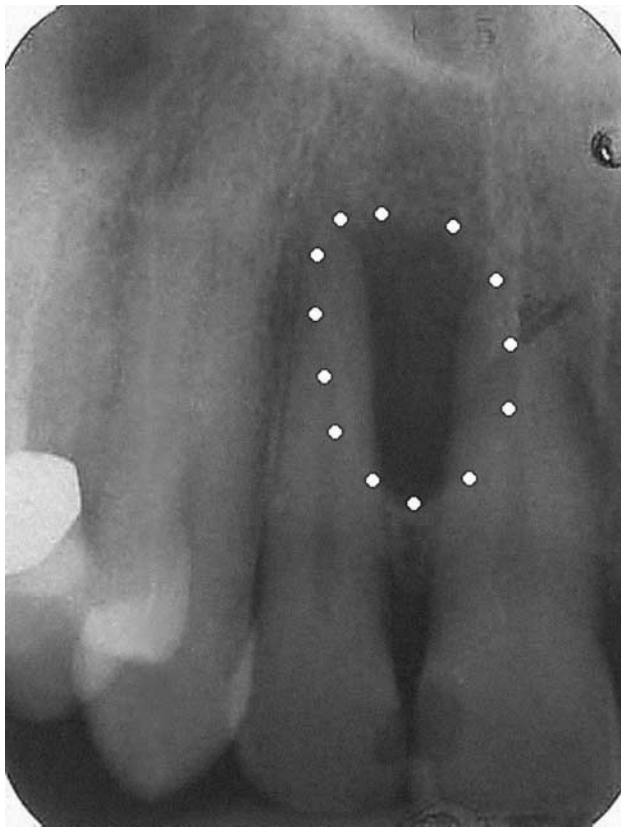


Figure 5. Odontogenic keratocyst between roots of right maxillary incisors (circled by white dots).

ence of residual epithelium or an epithelial remnant after enucleation of the cyst.⁴⁰ Another factor is the presence of satellite cysts in the cyst's wall.⁴¹ OKCs do not develop through an increase in osmotic pressure in the lumen like other cysts.³³ They have an active epithelial lining with a more rapid rate of proliferation than that of radicular cysts.⁴² The increased cell activity is evident by the presence of elevated level of oxidative enzymes and acid phosphatase, which indicate high metabolic and lysosomal activities.^{9,33} In addition, OKCs' connective tissue walls have an increased level of the collagenase enzyme leucine aminopeptidase.^{4,9}

Ahlfors and colleagues⁴ have proposed that OKCs should be regarded as a benign cystic neoplasm rather than a developmental cyst, and Bataineh and al Qudah⁴³ advocate jaw resection as the favorable treatment for an OKC.⁴³ OKCs require complete removal. A spectrum of treatments have been recommended, ranging from enucleation to resection without a continuity defect.⁴³⁻⁴⁶ The recurrence rate reported for resection is 0 percent; however, resection can have

high morbidity.⁴⁷ The recurrence rate associated with enucleation with adjunctive therapy such as cryosurgery and decompression (1-8 percent) is lower than that associated with enucleation alone (17-56 percent).⁴⁷ Postoperative follow-up with regular radiographic examination is important with OKCs because of the potential for recurrence. OKCs usually recur within five years after surgery,^{16,17} but they can recur more than 15 years later.^{38,43}

The destructive and high recurrence potential of OKCs and their ability to mimic other jaw cysts highlight the importance of including OKCs in the differential diagnosis of radiolucent jaw lesions, especially those occurring in the maxillary canine region. It also is important to evaluate microscopically any tissue taken from radiolucent jaw lesions to rule out OKCs and other serious pathological processes.

CONCLUSION

The anterior maxilla, specifically in the canine region, is the most common location for the OKC in the maxilla. OKCs commonly are mistaken for inflammatory lesions of endodontic origin or for lateral periodontal cysts. Due to the high recurrence rate and aggressive behavior of OKCs, all tissue removed should be submitted for microscopic evaluation and a definitive diagnosis. ■

Dr. Ali is an oral and maxillofacial pathology resident, University of Florida, College of Dentistry, Department of Oral and Maxillofacial Surgery and Diagnostic Sciences, P.O. Box 100414, Gainesville, Fla. 32610-0414, e-mail "mdentist@yahoo.com". Address reprint requests to Dr. Ali.

Dr. Baughman is a professor emeritus, University of Florida, and the director, Oral, Head and Neck Pathology, Ameripath/Central Florida, Hawthorne, Fla.

1. Cawson RA, Odell EW. Essentials of oral pathology and oral medicine. 6th ed. New York: Churchill Livingstone; 1998:97.
2. Daley TD, Wysocki GP, Pringle GA. Relative incidence of odontogenic tumors and oral and jaw cysts in a Canadian population. *Oral Surg Oral Med Oral Pathol* 1994;77:276-80.
3. Kreidler JF, Raubenheimer EJ, van Heerden WF. A retrospective analysis of 367 cystic lesions of the jaws: the Ulm experience. *J Craniomaxillofac Surg* 1993;21:339-41.
4. Ahlfors E, Larsson A, Sjögren S. The odontogenic keratocyst: a benign cystic tumor? *J Oral Maxillofac Surg* 1984;42:10-9.
5. Radden BG, Reade PC. Odontogenic cysts: a review and clinicopathological study of 368 odontogenic cysts. *Aust Dent J* 1973;18:218-25.
6. Kramer IR, Pindborg JJ, Shear M. The WHO histological typing of odontogenic tumours: a commentary on the second edition. *Cancer* 1992;70:2988-94.
7. Tsukamoto G, Sasaki A, Akiyama T, et al. A radiologic analysis of dentigerous cysts and odontogenic keratocysts associated with a mandibular third molar. *Oral Surg Oral Med Oral Pathol Oral Radiol Endod* 2001;91:743-7.
8. Payne TF. An analysis of the clinical and histopathologic parameters of the odontogenic keratocyst. *Oral Surg Oral Med Oral Pathol* 1972;33:538-46.
9. Magnusson BC. Odontogenic keratocysts: a clinical and histological

- study with special reference to enzyme histochemistry. *J Oral Pathol* 1978;7:8-18.
10. Shear M. Developmental odontogenic cysts: an update. *J Oral Pathol Med* 1994;23:1-11.
 11. Brannon RB. The odontogenic keratocyst: a clinicopathologic study of 312 cases, part I—clinical features. *Oral Surg Oral Med Oral Pathol* 1976;42:54-72.
 12. Browne RM. The odontogenic keratocyst: clinical aspects. *Br Dent J* 1970;128:225-31.
 13. Myoung H, Hong SP, Lee JI, et al. Odontogenic keratocyst: review of 256 cases for recurrence and clinicopathologic parameters. *Oral Surg Oral Med Oral Pathol Oral Radiol Endod* 2001;91:328-33.
 14. Nohl FS, Gulabivala K. Odontogenic keratocyst as periradicular radiolucency in the anterior mandible: two case reports. *Oral Surg Oral Med Oral Pathol Oral Radiol Endod* 1996;81:103-9.
 15. Wright BA, Wysocki GP, Larder TC. Odontogenic keratocysts presenting as periapical disease. *Oral Surg Oral Med Oral Pathol* 1983;56:425-9.
 16. Garlock JA, Pringle GA, Hicks ML. The odontogenic keratocyst: a potential endodontic misdiagnosis. *Oral Surg Oral Med Oral Pathol Oral Radiol Endod* 1998;85:452-6.
 17. Meara JG, Li KK, Shah SS, Cunningham MJ. Odontogenic keratocysts in the pediatric population. *Arch Otolaryngol Head Neck Surg* 1996;122:725-8.
 18. Neville BW, Mishkin DJ, Traynham RT. The laterally positioned odontogenic keratocyst. a case report. *J Periodontol* 1984;55:98-102.
 19. Neville BW, Damm DD, Brock T. Odontogenic keratocysts of the midline maxillary region. *J Oral Maxillofac Surg* 1997;55:340-4.
 20. Omura S, Kawabe R, Kobayashi S, Mizuki N. Odontogenic keratocyst appearing as a soap-bubble or honeycomb radiolucency: report of a case. *J Oral Maxillofac Surg* 1997;55:185-9.
 21. Hayashi K, Tozaki M, Yoshida N, Fukuda K, Tanabe H. Dynamic multislice helical CT of ameloblastoma and odontogenic keratocyst: correlation between contrast enhancement and angiogenesis. *J Comput Assist Tomogr* 2002;26:922-6.
 22. MacDonald-Jankowski DS. The involvement of the maxillary antrum by odontogenic keratocysts. *Clin Radiol* 1992;45:31-3.
 23. Marzella ML, Poon CY, Peck R. Odontogenic keratocyst of the maxilla presenting as periodontal abscess. *Singapore Dent J* 2000;23:45-8.
 24. Lehrman BJ, Mayer DP, Tidwell OF, Brooks ML. Computed tomography of odontogenic keratocysts. *Comput Med Imaging Graph* 1991;15:365-8.
 25. Panders AK, Hadders HN. Solitary keratocysts of the jaws. *J Oral Surg* 1969;27:931-8.
 26. Pindborg JJ, Hansen J. Studies on odontogenic cyst epithelium: clinical and roentgenologic aspects of odontogenic keratocysts. *Acta Pathol Microbiol Scand* 1963;58:283-94.
 27. Hodgkinson DJ, Woods JE, Dahlin DC, Tolman DE. Keratocysts of the jaw: clinicopathologic study of 79 patients. *Cancer* 1978;41:803-13.
 28. Chow HT. Odontogenic keratocyst: a clinical experience in Singapore. *Oral Surg Oral Med Oral Pathol Oral Radiol Endod* 1998;86:573-7.
 29. Kakarantza-Angelopoulou E, Nicolatou O. Odontogenic keratocysts: clinicopathologic study of 87 cases. *J Oral Maxillofac Surg* 1990;48:593-9.
 30. Hansen J. Keratocysts in the jaws. In: Husted E, Hjørtting-Hansen E. *Oral surgery: Transactions of the Second Congress of the International Association of Oral Surgeons, Copenhagen, Denmark, June 22-24, 1965*. Copenhagen, Denmark: Munksgaard; 1967:128-34.
 31. Forssell K, Sorvari TE, Oksala E. A clinical and radiographic study of odontogenic keratocysts in jaws. *Proc Finn Dent Soc* 1974;70:121-34.
 32. Haring JI, Van Dis ML. Odontogenic keratocysts: a clinical, radiographic, and histopathologic study. *Oral Surg Oral Med Oral Pathol* 1988;66:145-53.
 33. Zachriades N, Papanicolaou S, Triantafyllou D. Odontogenic keratocysts: review of the literature and report of sixteen cases. *J Oral Maxillofac Surg* 1985;43:177-82.
 34. Stajic Z, Paljm A. Keratinization of radicular cyst epithelial lining or occurrence of odontogenic keratocyst in the periapical region? *Int J Oral Maxillofac Surg* 1987;16:593-5.
 35. Fantasia JE. Lateral periodontal cyst: an analysis of forty-six cases. *Oral Surg Oral Med Oral Pathol* 1979;48:237-43.
 36. Wetmore SJ, Billie JD, Howe A, Wetzel W. Odontogenic keratocyst: diagnosis and treatment. *Otolaryngol Head Neck Surg* 1983;91:167-72.
 37. Forssell K, Forssell H, Kahnberg KE. Recurrence of keratocysts: a long-term follow-up study. *Int J Oral Maxillofac Surg* 1988;17:25-8.
 38. Vedtofte P, Praetorius F. Recurrence of the odontogenic keratocysts in relation to clinical and histological features: a 20-year follow-up study of 72 patients. *Int J Oral Surg* 1979;8:412-20.
 39. Voorsmit RA, Stoelinga PJ, Van Haelst UJ. The management of keratocysts. *J Maxillofac Surg* 1981;9:228-36.
 40. Rud J, Pindborg JJ. Odontogenic keratocysts: a follow-up study of 21 cases. *J Oral Surg* 1969;27:323-30.
 41. Browne RM. The odontogenic keratocyst: histologic features and their correlation with clinical behavior. *Br Dent J* 1971;131:249-59.
 42. Brannon RB. The odontogenic keratocyst: a clinicopathologic study of 312 cases, part II—histologic features. *Oral Surg Oral Med Oral Pathol* 1977;43:233-55.
 43. Bataineh AB, al Qudah M. Treatment of mandibular odontogenic keratocysts. *Oral Surg Oral Med Oral Pathol Oral Radiol Endod* 1998;86:42-7.
 44. Schmidt BL, Pogrel MA. The use of enucleation and liquid nitrogen cryotherapy in the management of odontogenic keratocysts. *J Oral Maxillofac Surg* 2001;59:720-5.
 45. Tucker WM, Pleasants JE, MacComb WS. Decompression and secondary enucleation of a mandibular cyst: report of a case. *J Oral Surg* 1972;30:669-73.
 46. Eyre J, Zakrzewska JM. The conservative management of large odontogenic keratocyst. *Br J Oral Maxillofac Surg* 1985;23:195-203.
 47. Blanas N, Freund B, Schwartz M, Furst IM. Systematic review of the treatment and prognosis of the odontogenic keratocyst. *Oral Surg Oral Med Oral Pathol Oral Radiol Endod* 2000;90:553-8.